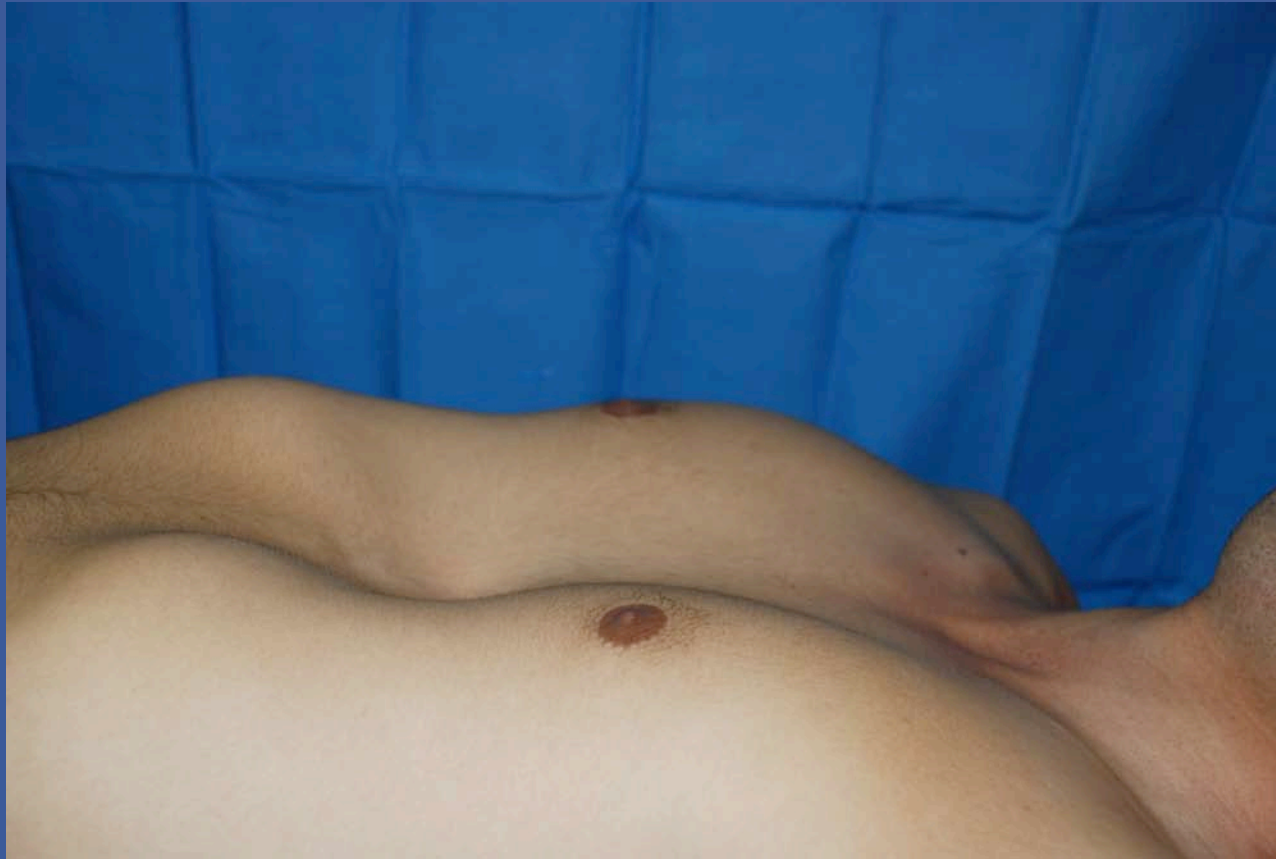

Pectus Excavatum o Carinatum

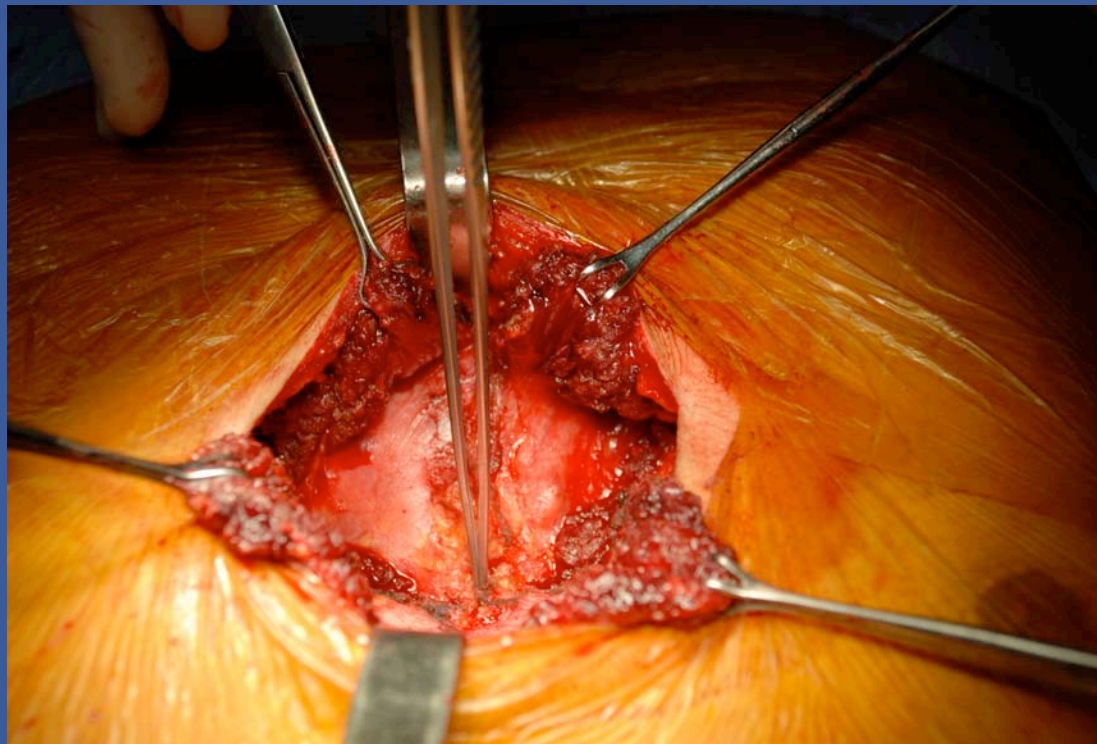
Corrección con técnica mixta
Ravitch modificado + Malla

Claudio Suárez
Clínica Santa María

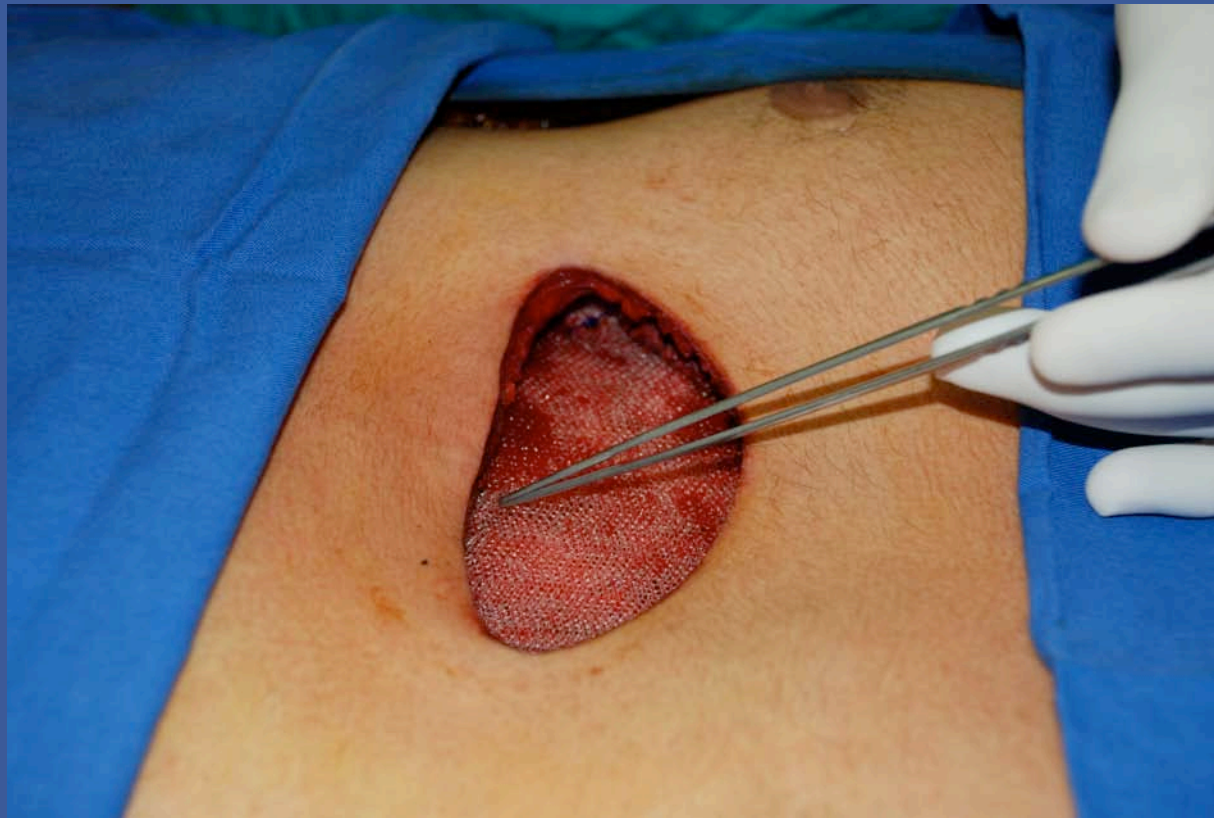
Pectus excavatum



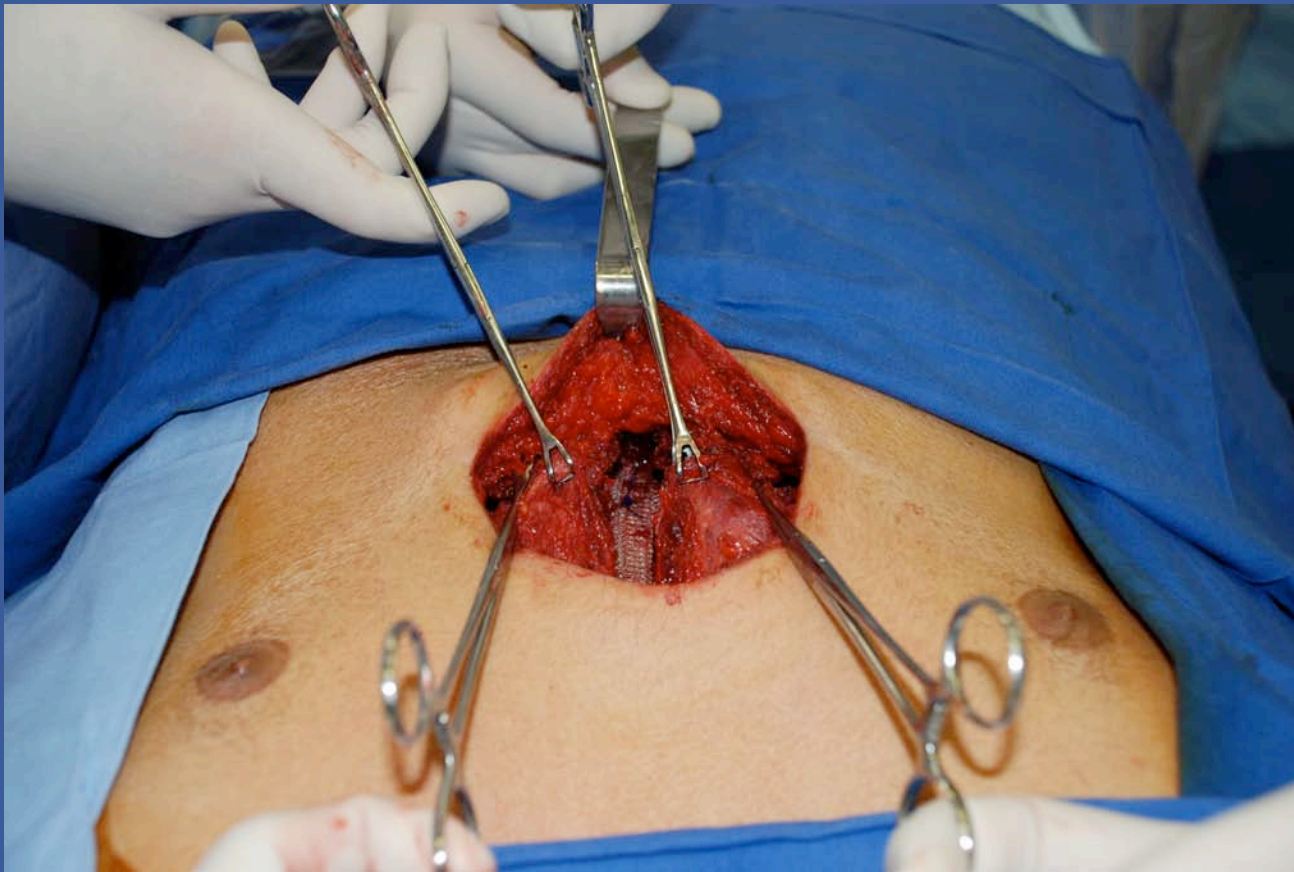
Resecados los cartílagos y tallados los colgajos



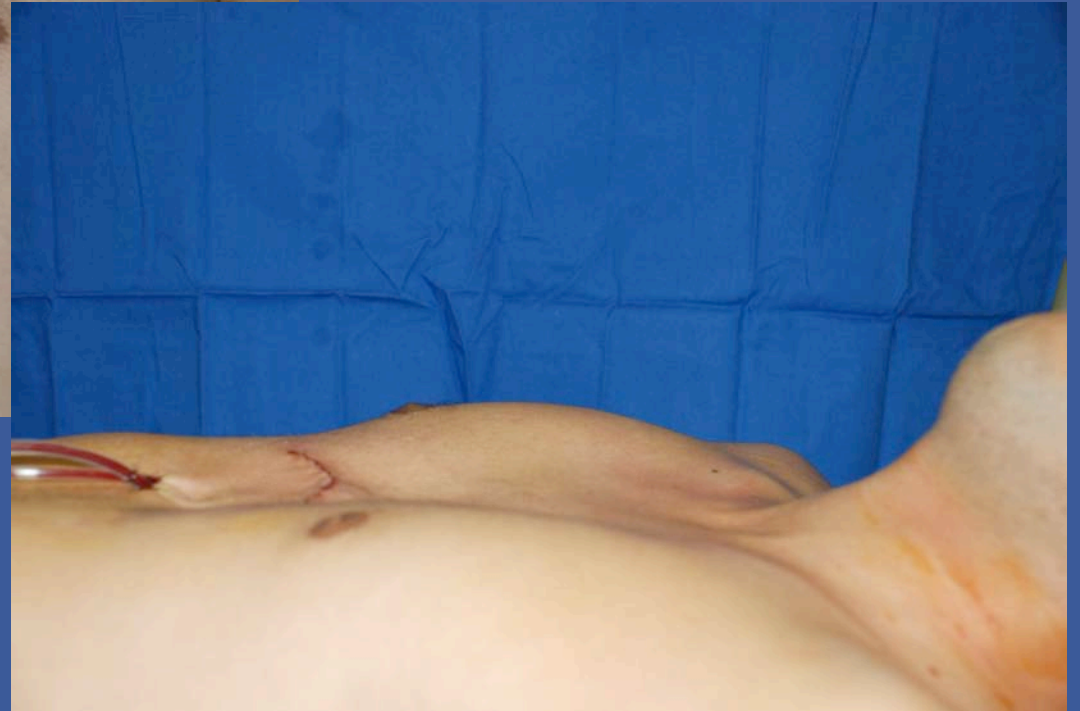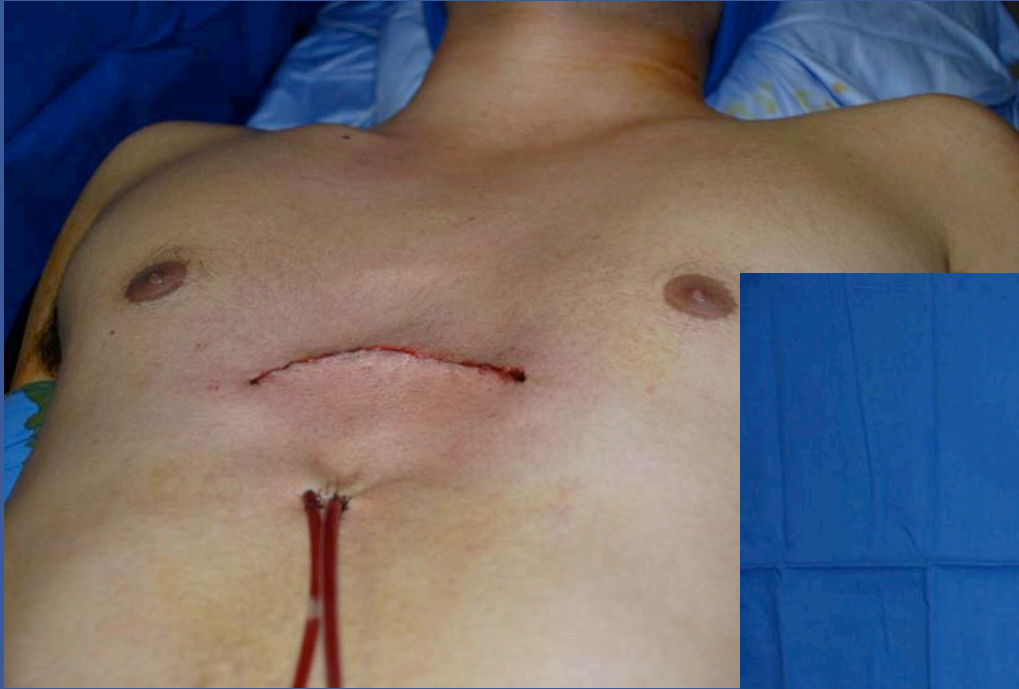Malla de márlex doble



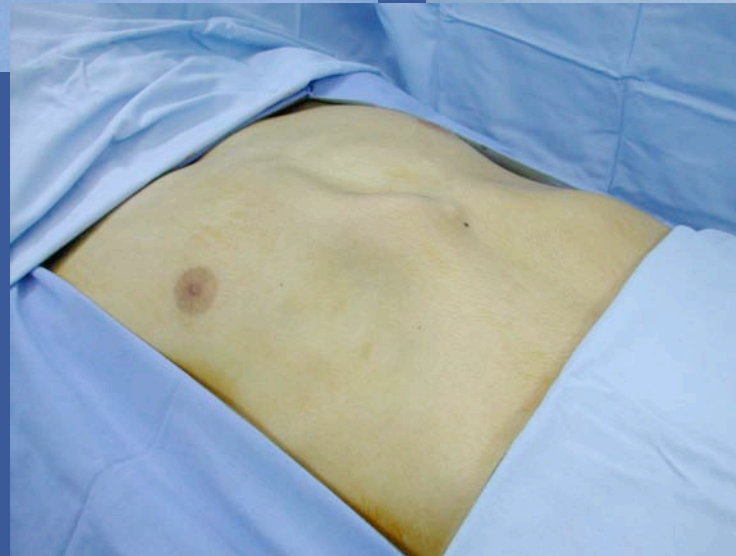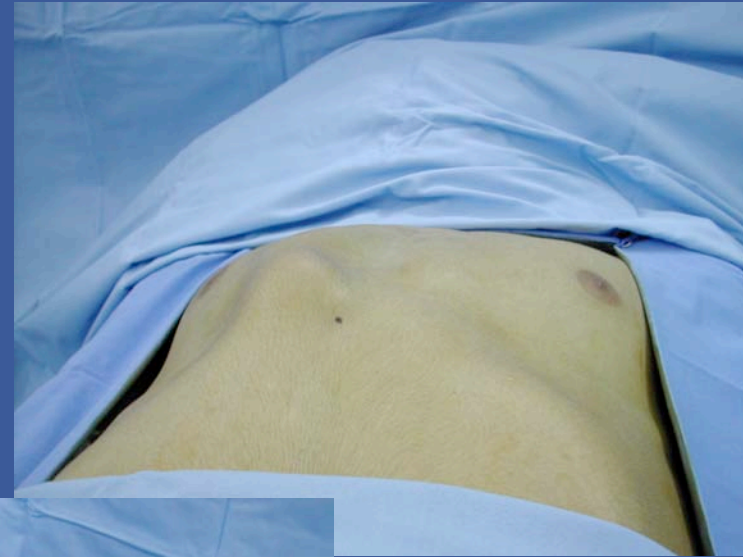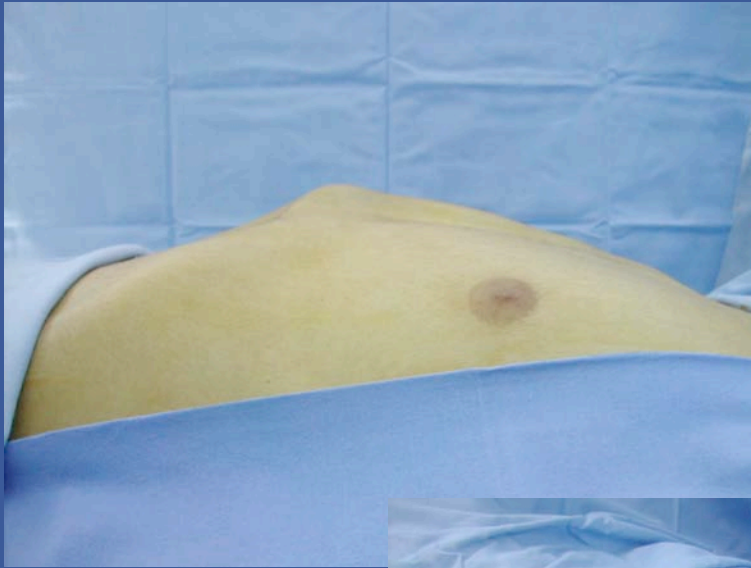
Colgajos de músculos presentados



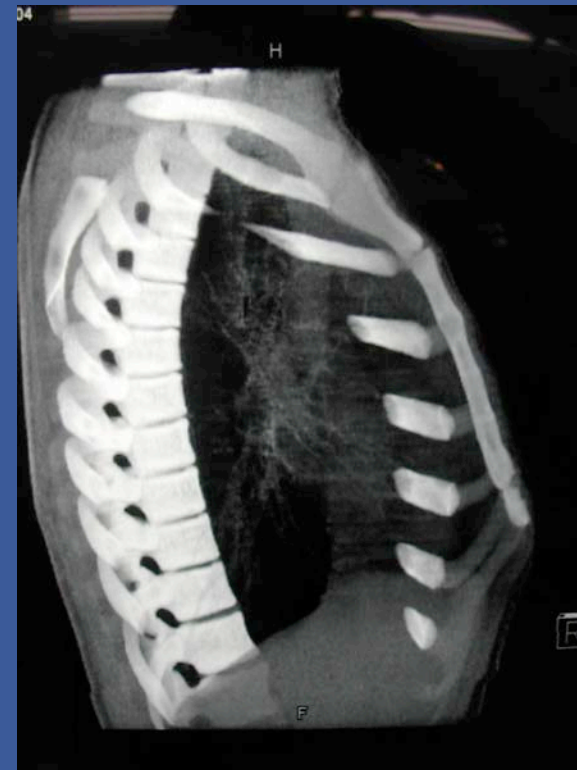
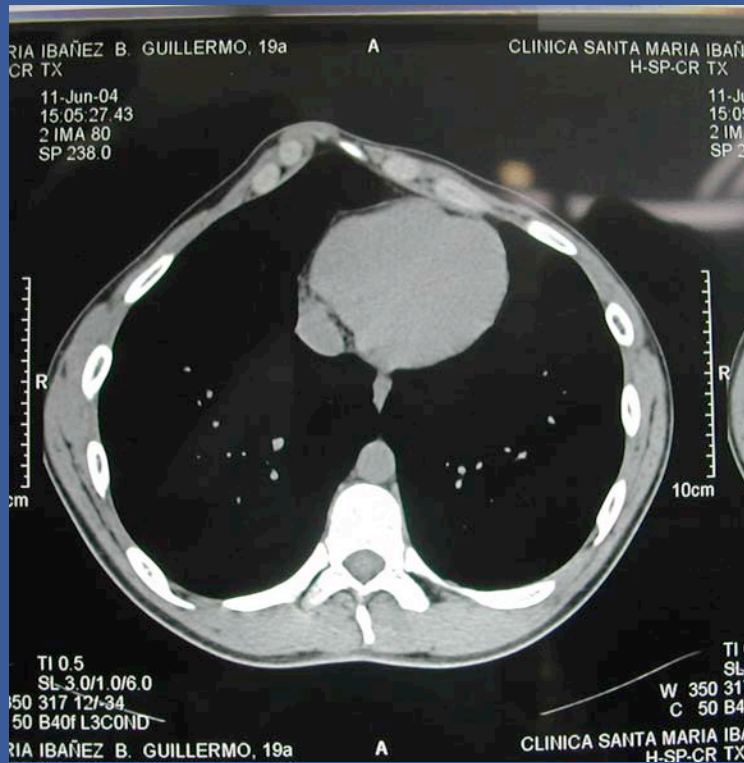
Resultado postoperatorio inmediato



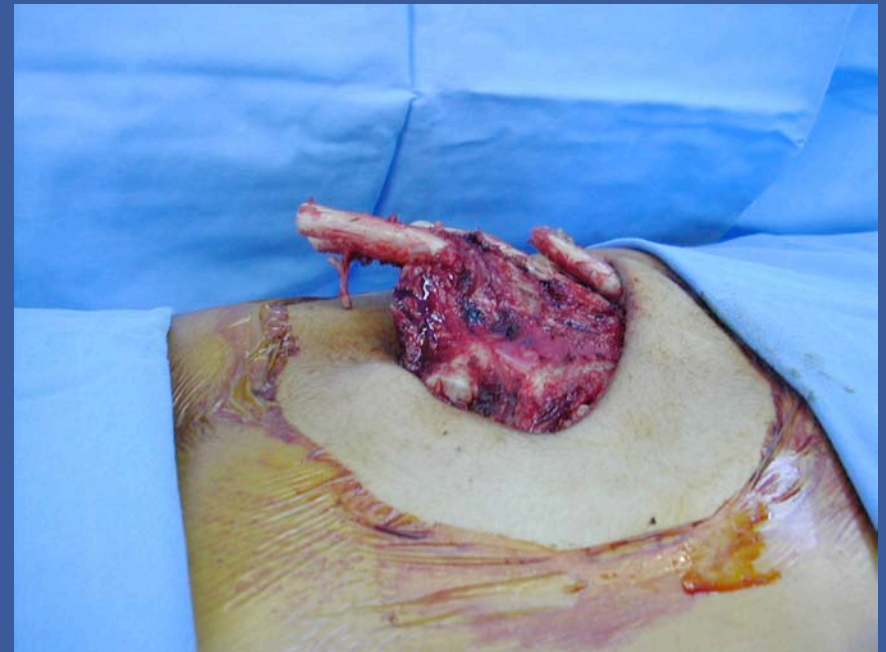
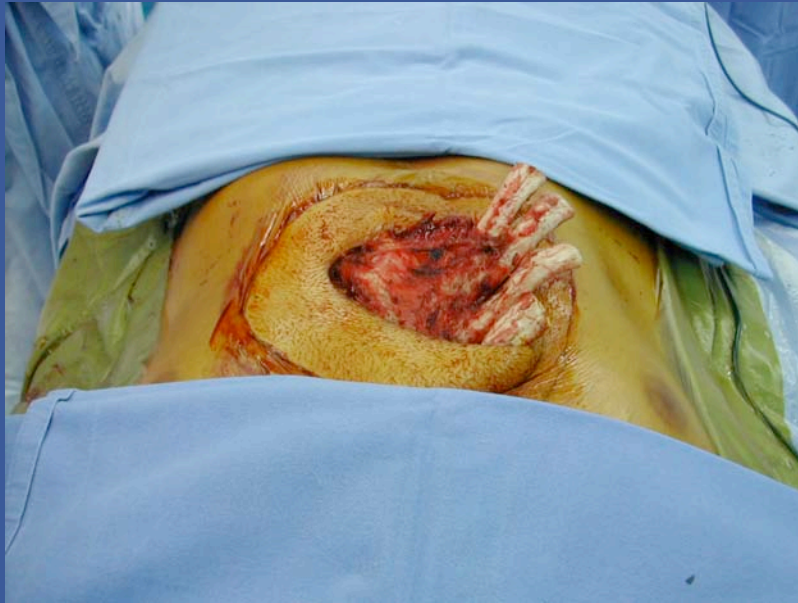Pectus carinatum



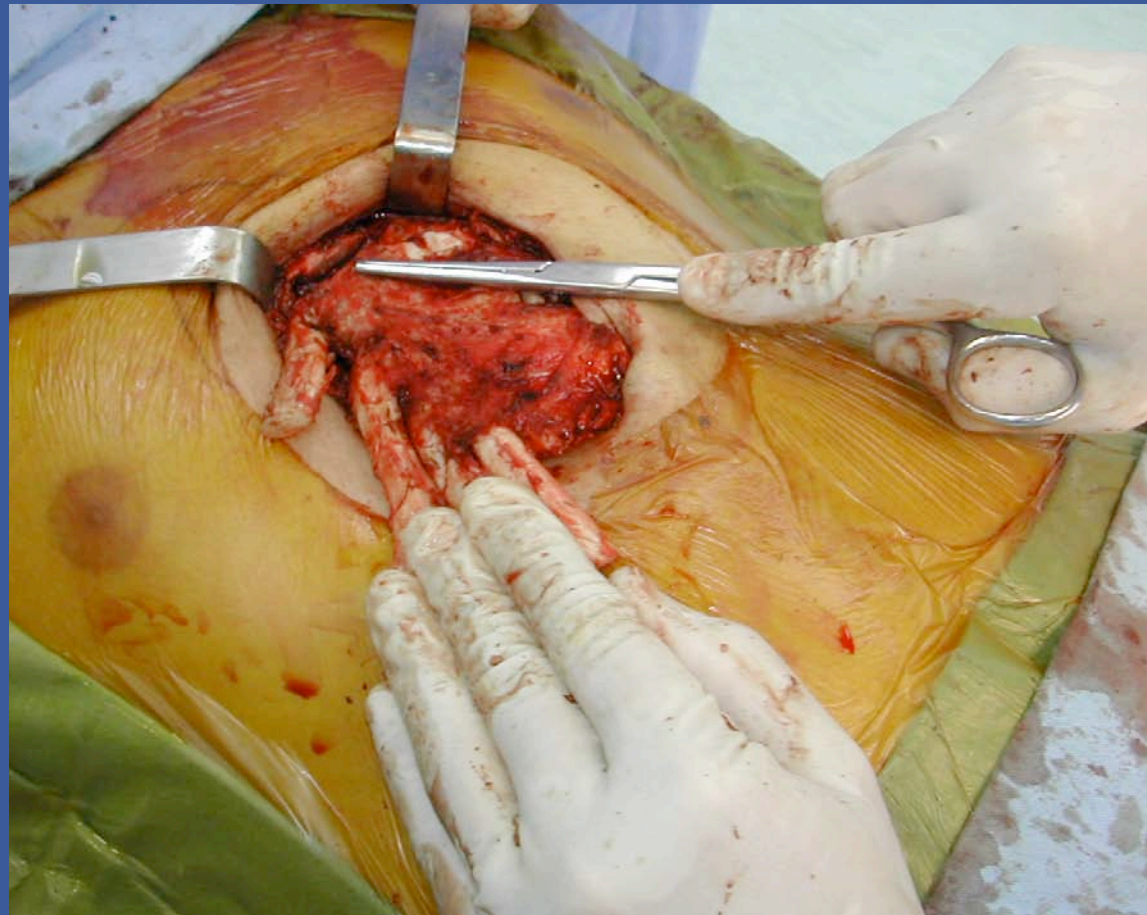
Pectus carinatum



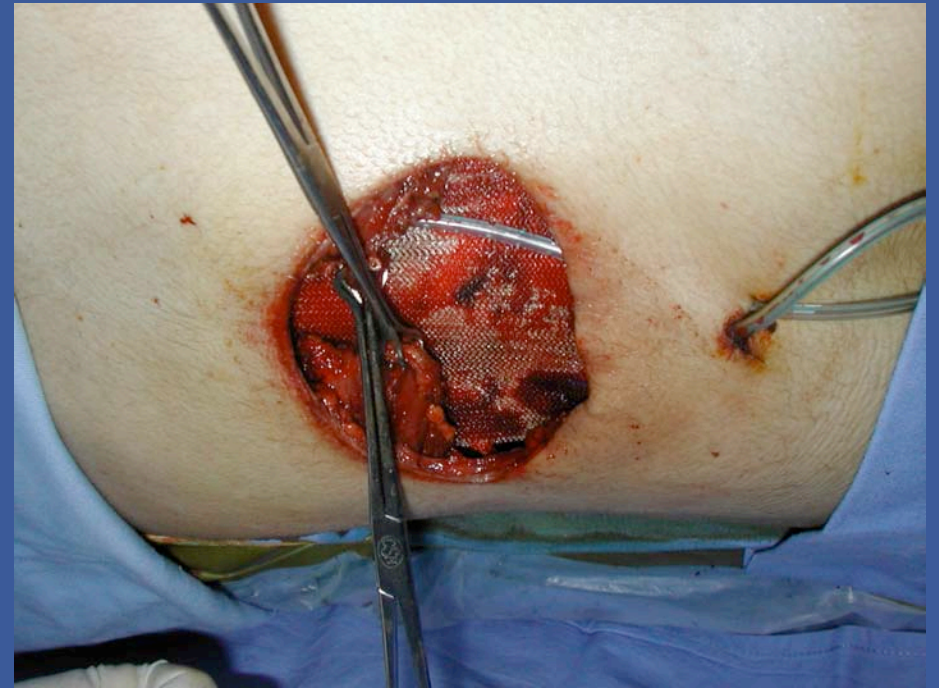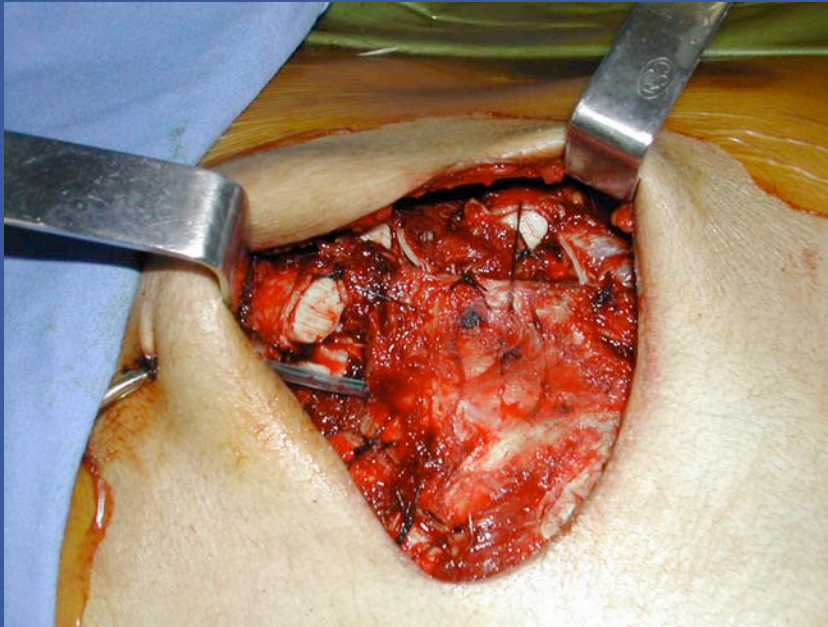
Disección de cartílagos y esternón



Sección de cartílagos y esternón



Plastía y malla márlex



Resultado postoperatorio inmediato

